

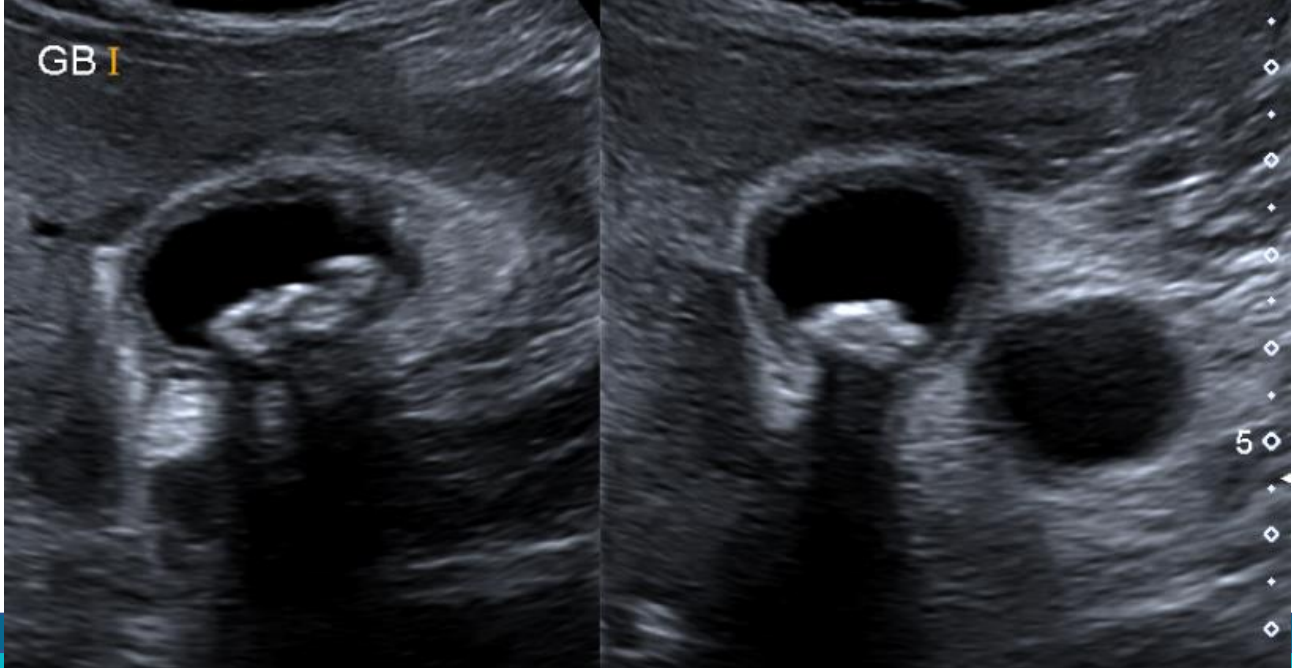
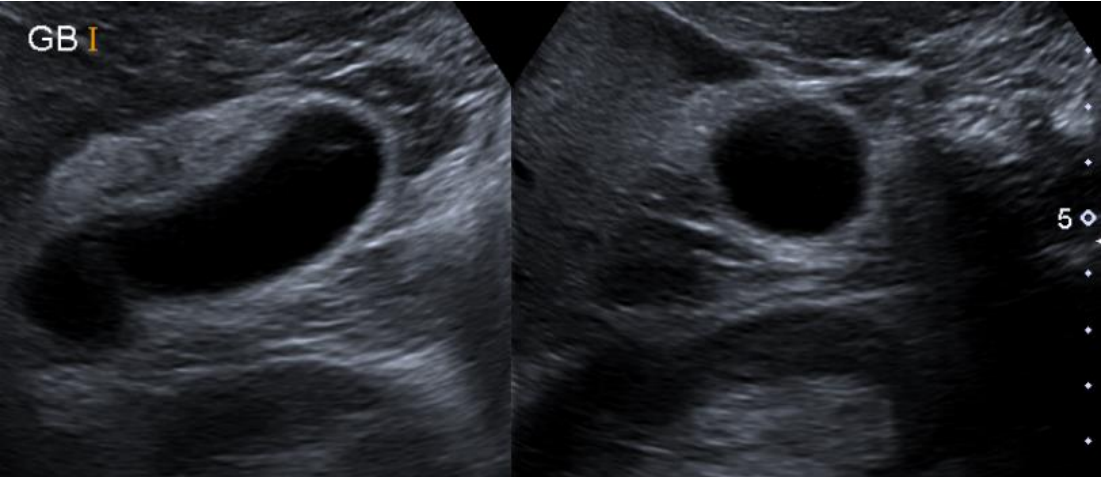
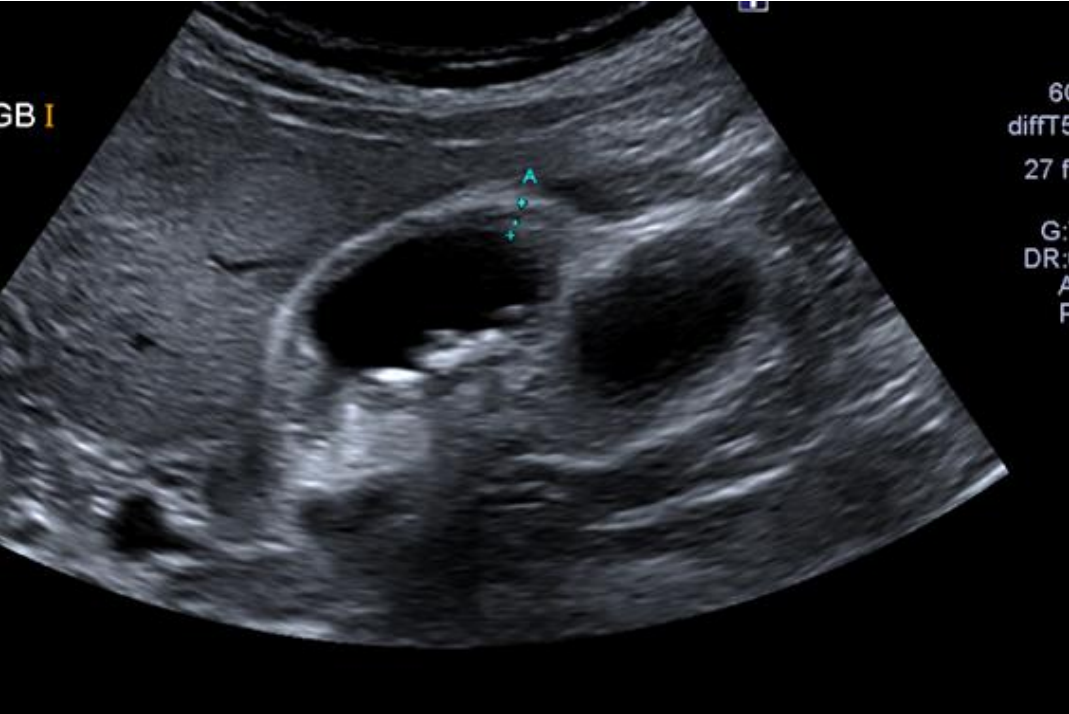
General Medical Case no.6

February 2023

Clinical details: GP referral

48 year old overweight female. H/O postprandial RUQ pain on and off for six months. No relief from PPIs.

BMUS



Do not progress to the next slide until you have attempted to write a report.

Ultrasound report

Abdominal ultrasound

No previous imaging for comparison.

The aorta, pancreas, spleen, both kidneys and liver look normal. No intrahepatic biliary dilatation. CD not dilated at 5mm.

The gallbladder wall is thickened and the lumen contains several small mobile stones. A duplicate gallbladder with no visible stones is seen inferior to this gallbladder.

Conclusion:

Gallstones with evidence of cholecystitis. Duplicate gallbladder noted.

Fact File

Gallstones

- Prevalence: 10 – 15 % adults in USA and Europe
- Risk factors include Crohn's disease, diabetes, diet high in triglycerides and refined carbs, obesity
- Most people with gallstones are **asymptomatic** so practitioners must search carefully for other causes of RUQ pain
- Symptomatic gallstone disease may require laparoscopic cholecystectomy

Duplicate gallbladder

- Rare congenital variant involving an accessory gallbladder
- It carries no increased risk of stones or malignancy
- Incidence 1:4,000 live births
- Differentials include: Phrygian cap, choledocal cyst, gallbladder fold, gallbladder diverticulum